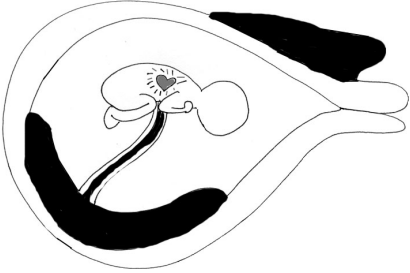

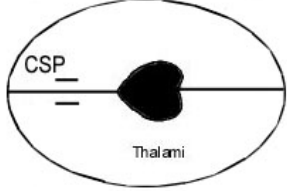
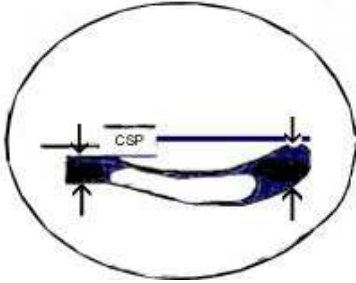
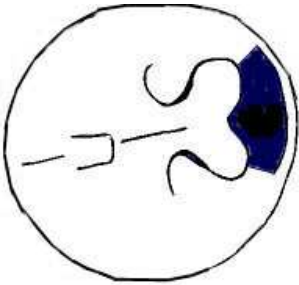

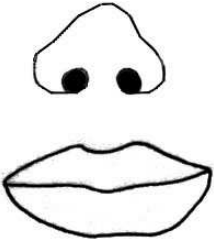

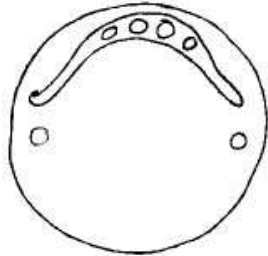
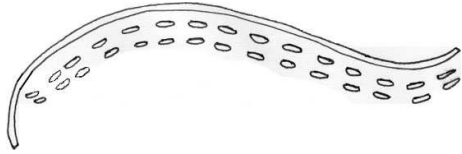


Pictogram of Standard Views with compliments by Dr Ilse Erasmus

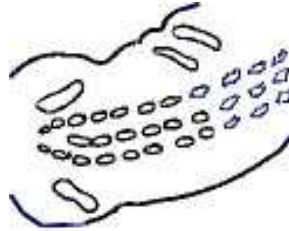
<p>Intrauterine, viable, placental position, no. of fetuses, cervix</p> 	<p>3VC, amniotic fluid</p> 	<p>BPD, HC, skull shape, midline, CSP, thalami</p> 
<p>Lateral ventricles: anterior and posterior horns (<10mm = N)</p> 	<p>Cerebellum, cisterna magna (N <10mm), nuchal skinfold (N <6mm)</p> 	<p>Profile check, chin, lips</p> 
<p>Nose and lips check to exclude clefts</p> 	<p>Orbits check, size distance</p> 	<p>Upper palate check to exclude cleft palate</p> 

Pictogram of Standard Views with compliments by Dr Ilse Erasmus

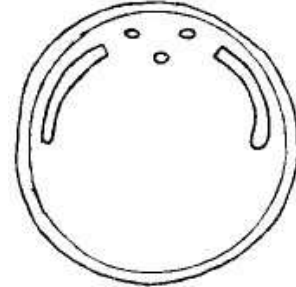
Spine check saggital /longitudinal view - check all vertebral segments for presence and skin covering from neck to sacrum



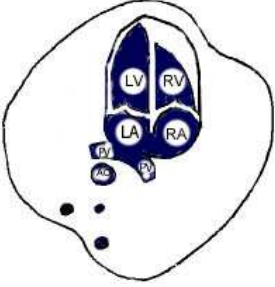




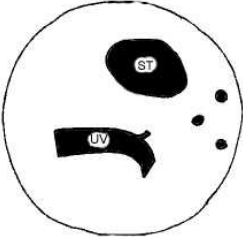


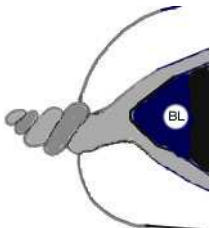

Spine check coronal view



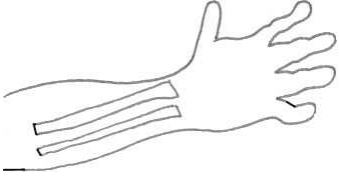
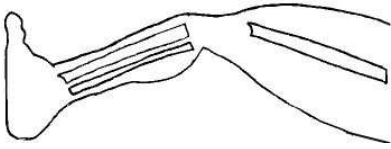

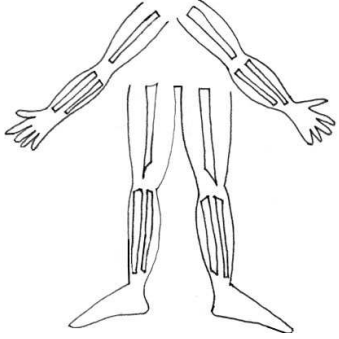
Spine check in transverse or axial plane for defects and vertebral splaying



Pictogram of Standard Views with compliments by Dr Ilse Erasmus

<p>4ch, apex left, axis septum, valve offsetting, foramen ovale, VSD check (obligatory view)</p> 	<p>"Trouser" sign of RVOT (advanced/ extra view)</p> 	<p>5ch view Check aorta outflow, aorta and pulm vessel crossing exclude co-arctation (advanced/ extra view)</p> 
<p>Aortic arch head and neck vessels (obligatory view)</p> 	<p>Ductal arch (obligatory view)</p> 	<p>Heart Rate: Bradycardia < 100 bpm Tachycardia > 180 bpm Heart Rhythm</p>
<p>Measure AC, check stomach, and umbilical vein TOF and Double bubble check</p> 	<p>Confirm 2 kidneys and check renal pelvises normal = (N ≤ 5mm)</p> 	<p>Check cord insertion and exclude exomphalos and gastroschisis</p> 
<p>Check presence of bladder, 2 supra vessal arteries= 3VC</p> 	<p>Check stomach below diaphragm</p> 	<p>Measurement checklist: BPD, HC, AC, FL, EFW, HL, NT, AFI</p>

Pictogram of Standard Views with compliments by Dr Ilse Erasmus

<p>Check that hand opens and no clinodactyly Measure Humerus length</p> 	<p>Check for clubfoot Measure Femur length</p> 	<p>Check for sandal gap</p> 
	<p>Fetal upper limbs Hands x 2 Radius x 2 ulna x 2 Humerus x 2</p> <p>Fetal lower limb Feet x 2 Tibia x 2 Fibula x 2 Femur x 2</p> <p>Check echogenicity, shape, movements, position</p>	