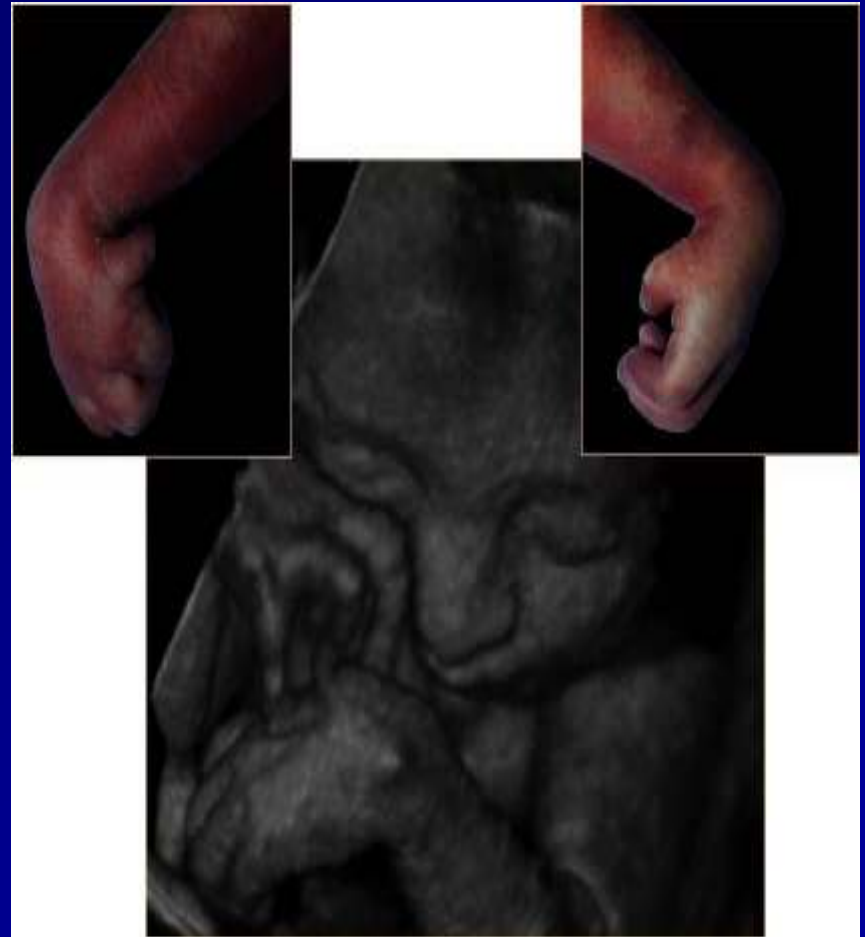


RISK ASSESSMENT BY SOFT MARKERS

MA DU TOIT
CONSULTANT OBSTETRICS &
GYNAECOLOGY
UOFS

INTRODUCTION

- Chromosome abnormalities 0.1% - 0.2%
- Conflicting evidence
- Common soft markers



MARKERS FOR CHROMOSOMAL ABNORMALITIES

- Syndrome Pattern (Snijders, Nicolaides)
- Major marker
 - Structural abnormality
 - Severe handicap
- Soft marker
 - Adjusted risk

Organ System	Major Marker	Soft Marker
SSS	Ventriculomegaly	Choroid cyst
Musculoskeletal	Abnormal hand, feet	Short long bones
Face	Facial cleft	Nasal hypoplasia
Neck	Cystic hygroma	Nuchal thickening
Cardiac	VSD	EICF
GIT	Duodenal atresia	Echogenic bowel
GUT	Hydronephrosis	Mild pyelectasis
Other	IUGR	Single artery

RISK ASSESSMENT

- Likelihood Ratio (LR)
 - LR= prevalence of marker in abnormal fetus/
prevalence of marker in normal fetus

Soft Marker	Likelihood Ratio (LR)
No soft marker	LR 0.3x
Mild Pyelectasis	LR 1.0x
Short Femur	LR 1.6x
Short Humerus	* LR 4.1
Echogenic Bowel	* LR 3.0x
Echogenic Intracardiac Focus	* LR 1.1x
Nuchal fold > 6mm	* LR 10.0x
Nasal bone hypoplasia	LR 50x

RISK ASSESSMENT

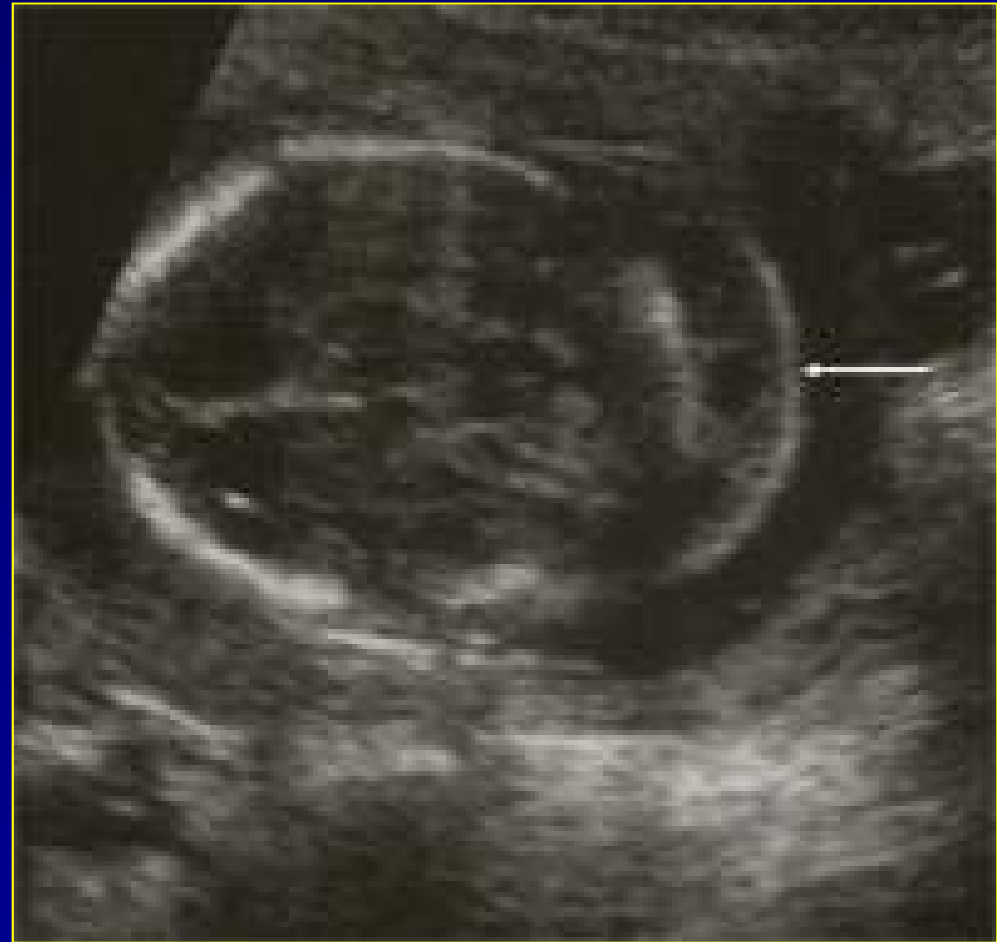- Likelihood Ratio (LR)
 - $LR = \frac{\text{prevalence of marker in abnormal fetus}}{\text{prevalence of marker in normal fetus}}$
- Adjusted Risk
 - Background risk x Factors from screening
- Absence of a marker
- High and low risk populations

SECOND TRIMESTER SOFT MARKERS

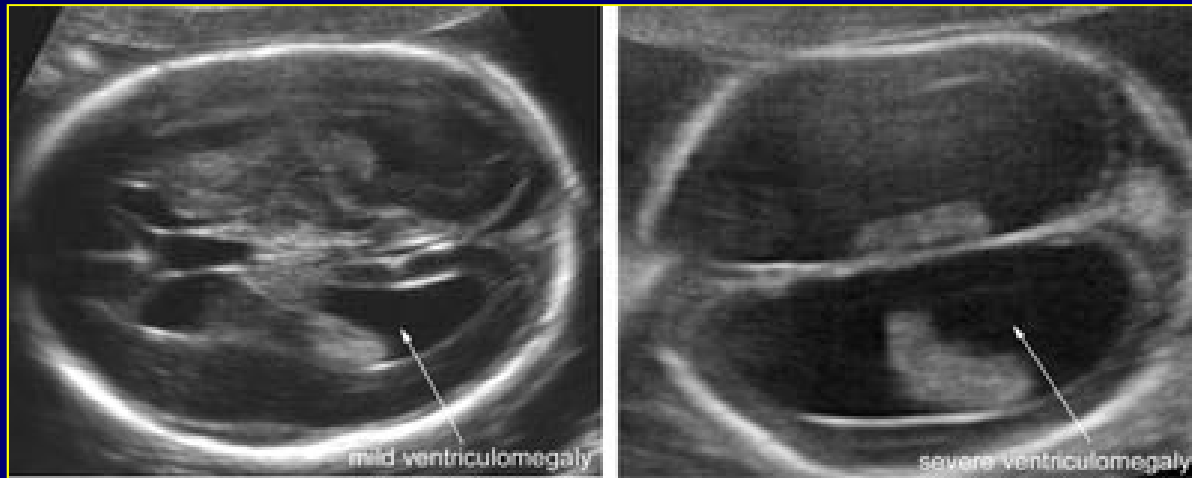
- 15- 23 Weeks gestation
- Level of evidence II
- Five most common soft markers
 - *Thickened Nuchal fold*
 - *Mild Ventriculomegaly*
 - *Echogenic bowel*
 - *Echogenic intracardiac focus*
 - *Choroid plexus cyst*

NUCHAL FOLD THICKENING

- LR: 10
- Position of measurement
- 5mm; 6mm
- Karyotyping (level II evidence)
- Cardiac abnormalities



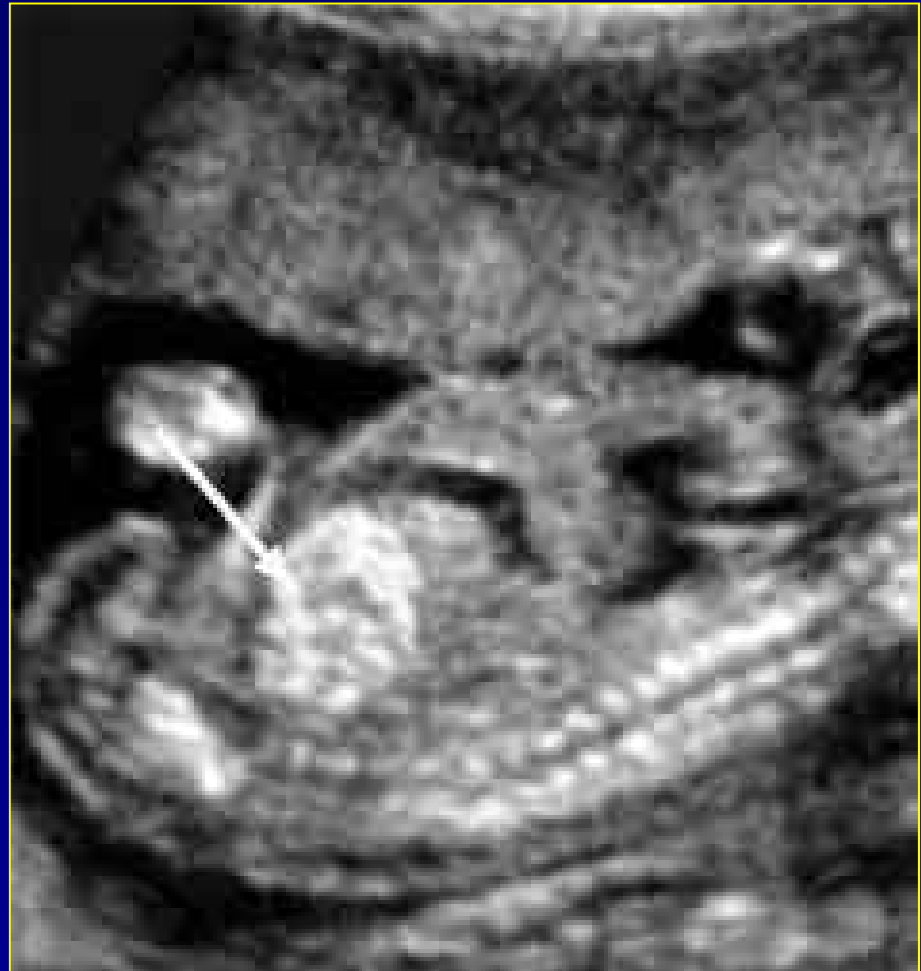MILD VENTRICULOMEGALY (MVM)



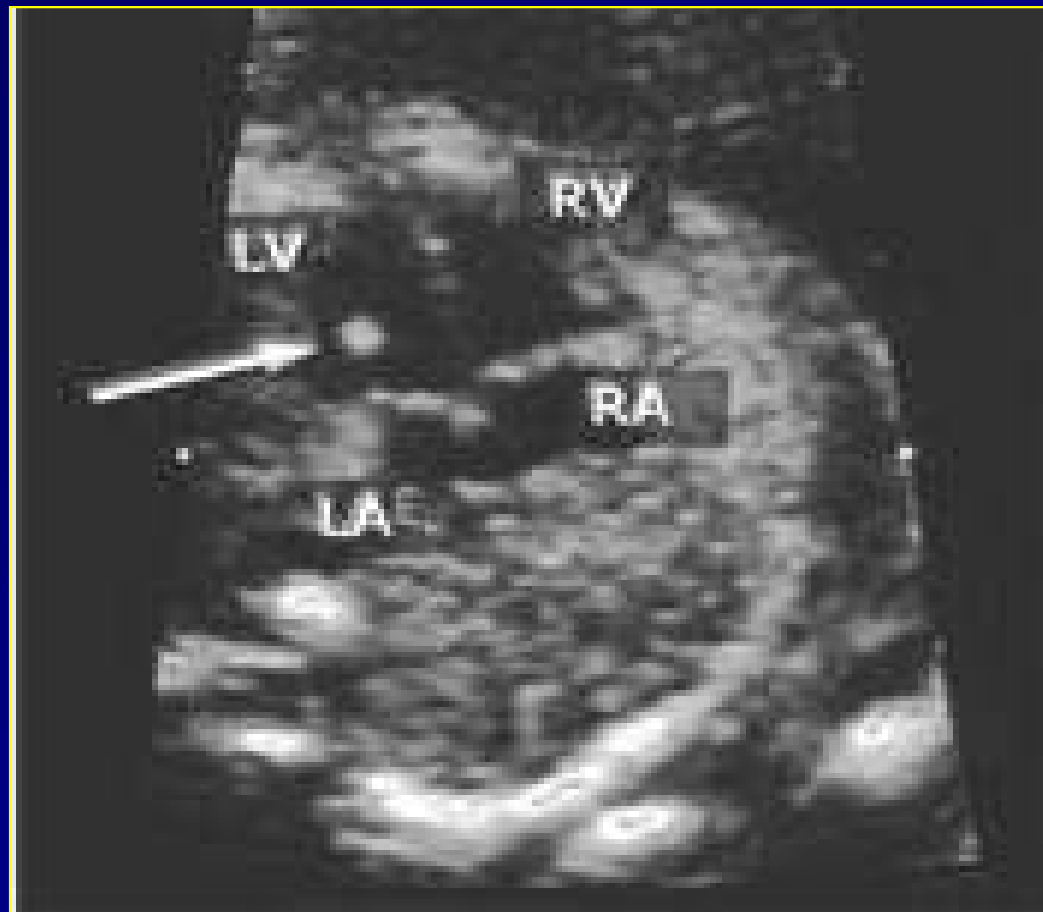
- LR: 9
- > 10mm; < 15 mm
- 3.8% Incidence
- 10 – 36% abnormal neurodevelopment

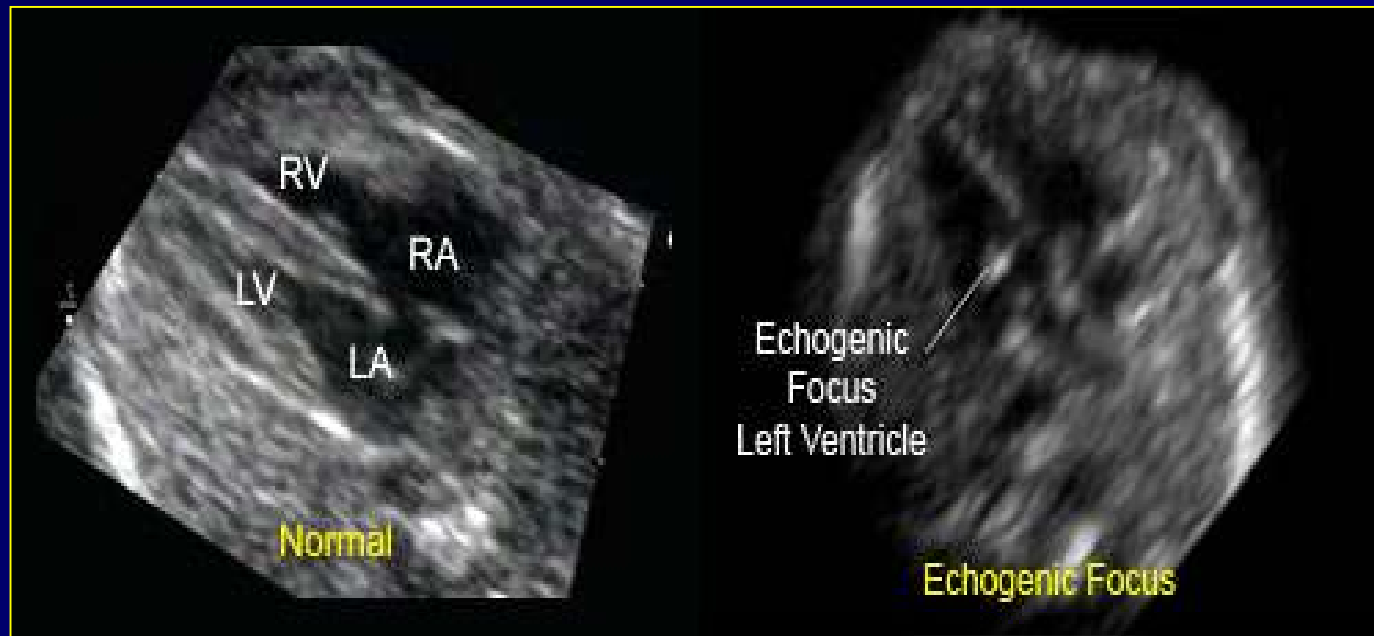
HYPER ECHOGENIC BOWEL

- LR: 3.0
- 0.1% to 1.4% in second trimester
- Grading system
- Other associations
- Follow up



ECHOGENIC INTRACARDIAC FOCUS (EICF)

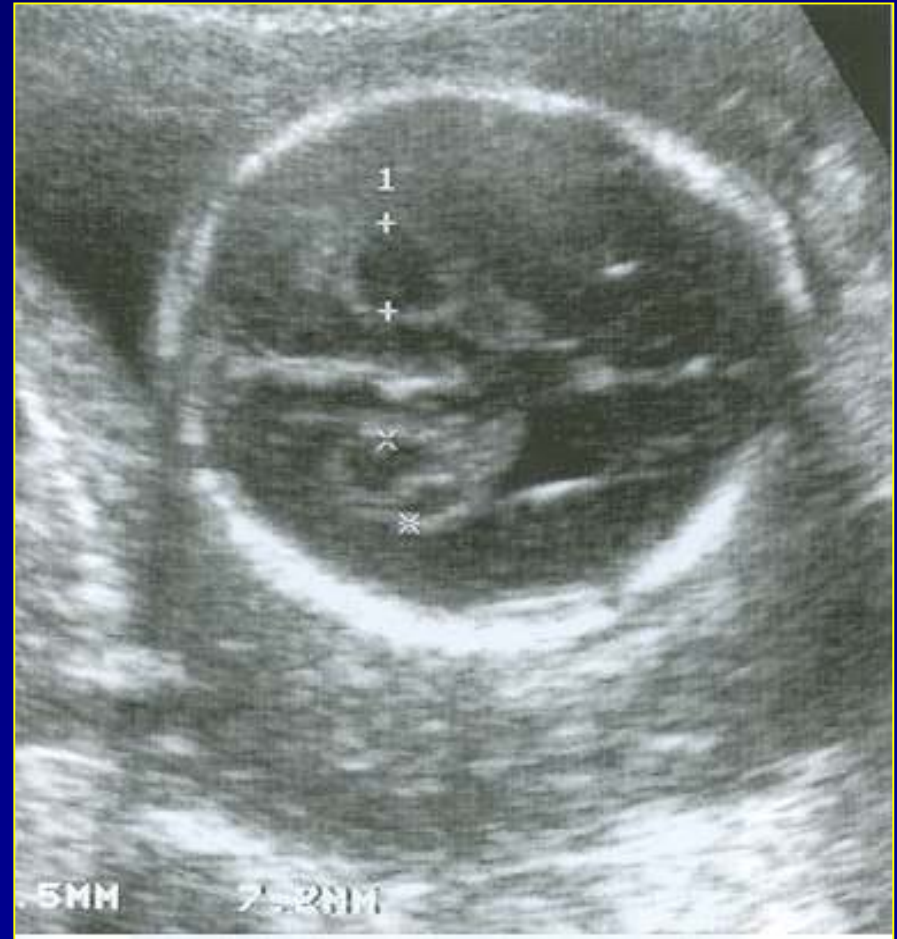

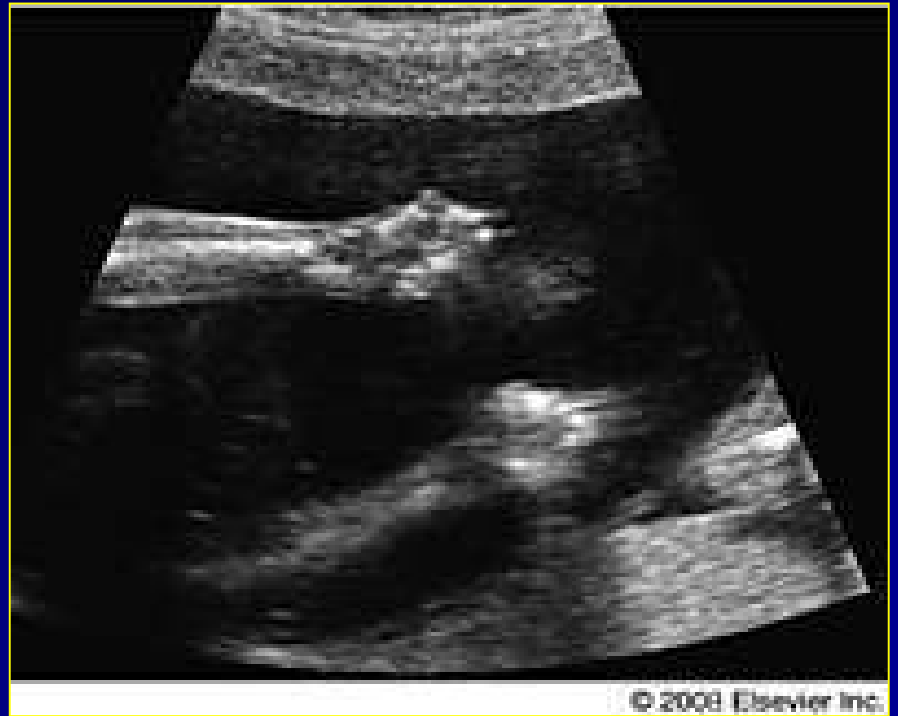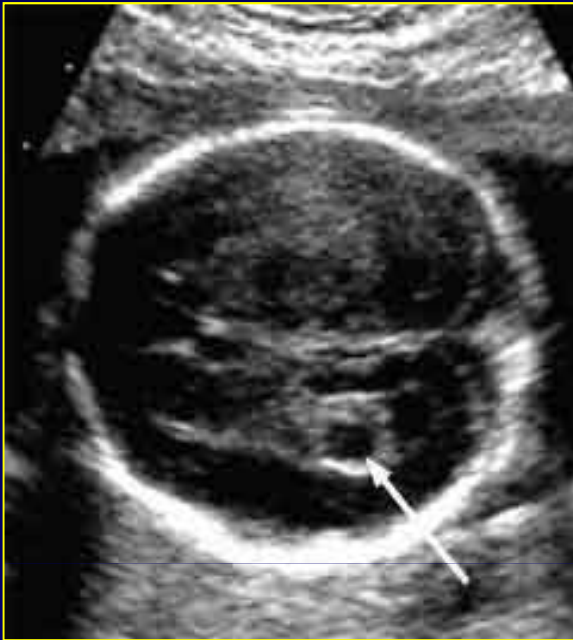


- Prevalence: 0.5 to 12%
- True and False EICF
- Individual risk assessment
- EICF in combination

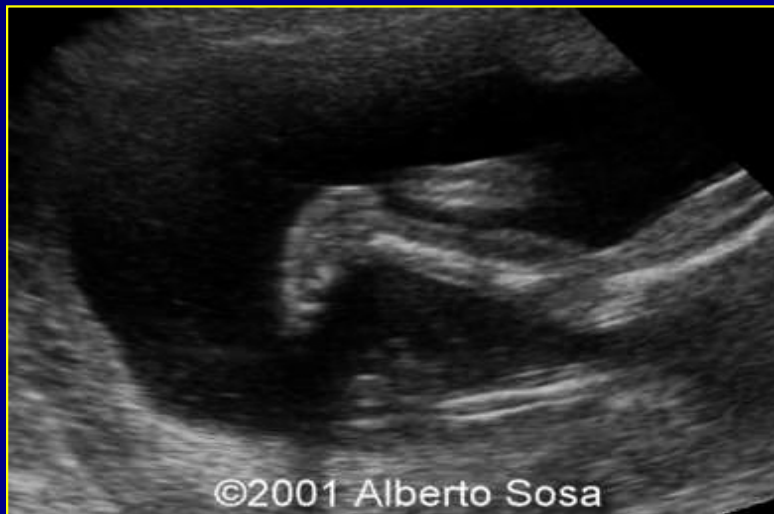CHOROID PLEXUS CYST

- 1 to 2.5% normal pregnancies
- Resolve at 26 weeks
- 80% < 10 mm
- Trisomy 18 > Down's
- Other findings





© 2008 Elsevier Inc.



©2001 Alberto Sosa

CONCLUSION

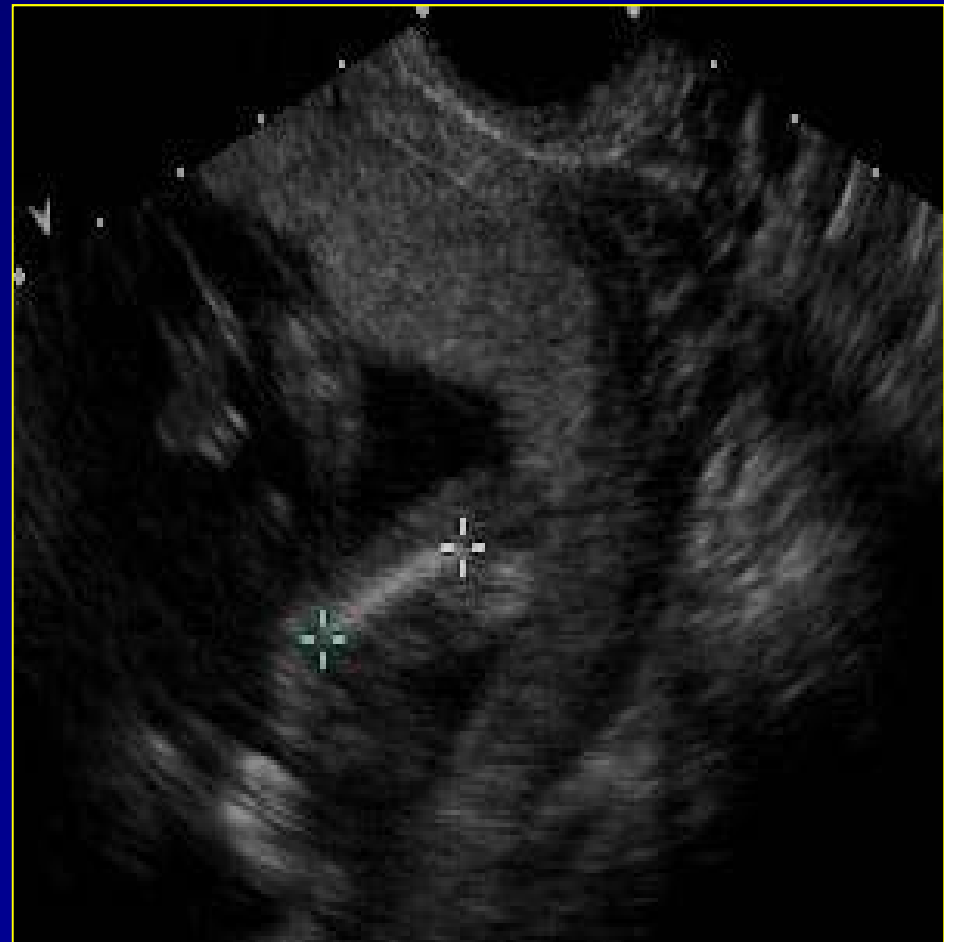
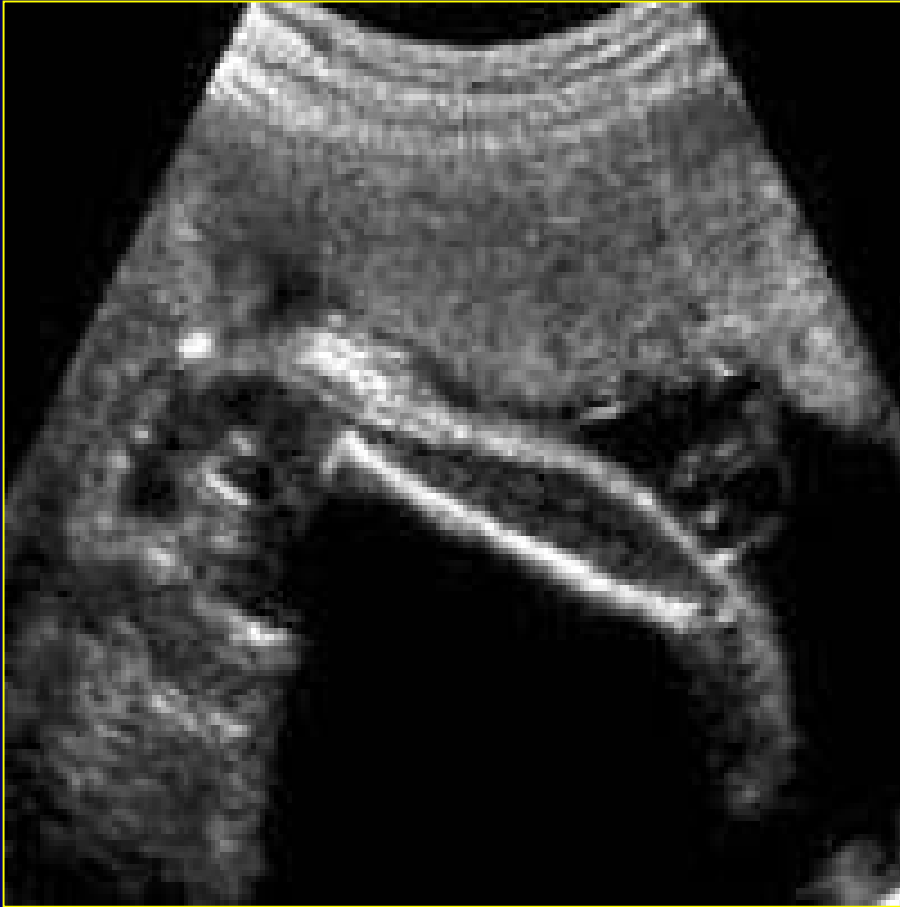- Conflicting evidence
- Abnormality = Detailed ultrasound
- High risk markers
- Correlation with risk factors
- Timely referral and confirmation



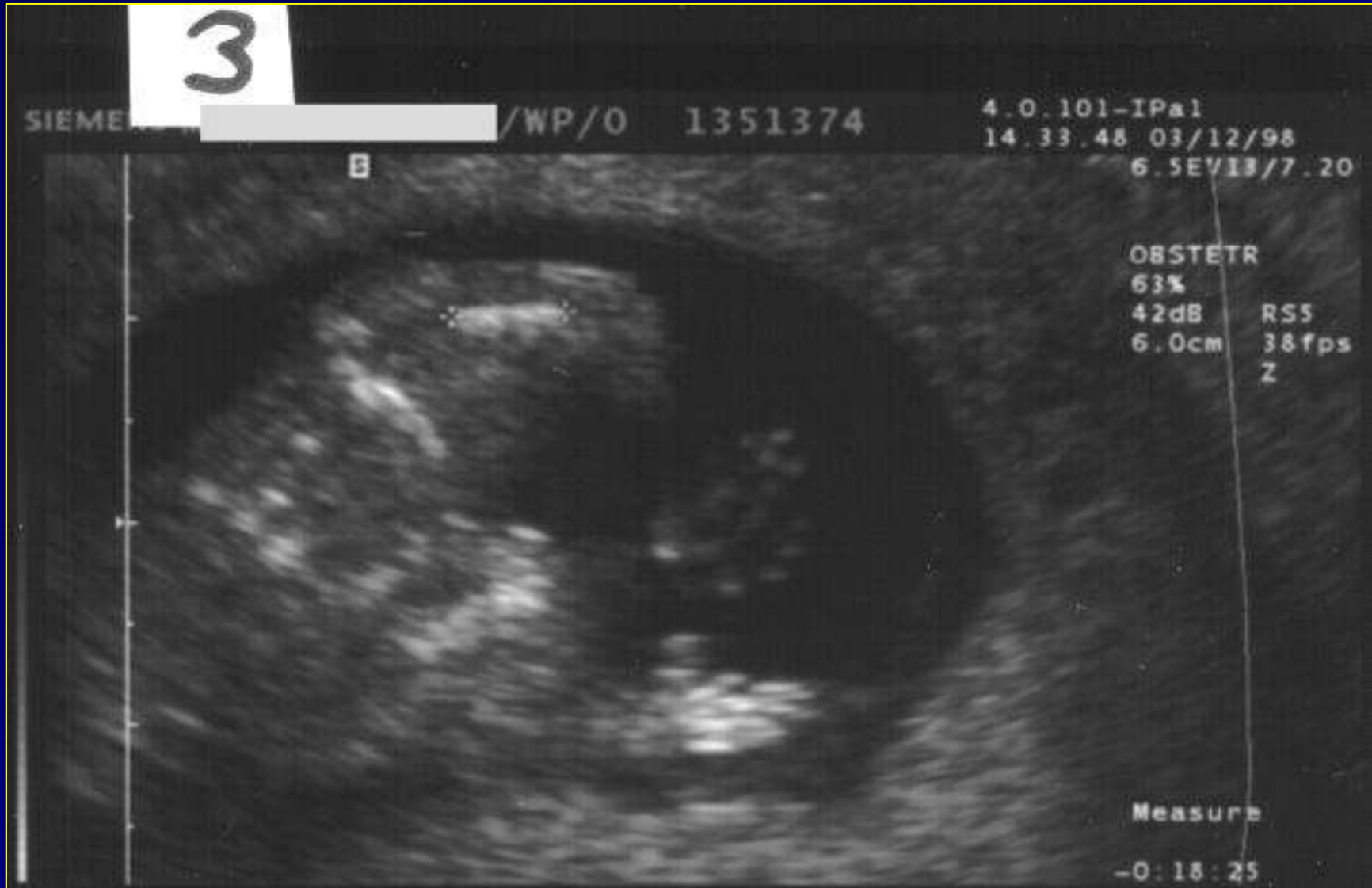SHORT LONG BONES

- < 2.5th percentile
- Down's syndrome
 - Femur LR 1.5
 - Humerus LR 4.1 (7.5)
- Evaluate other long bones; fetal chest

Femur

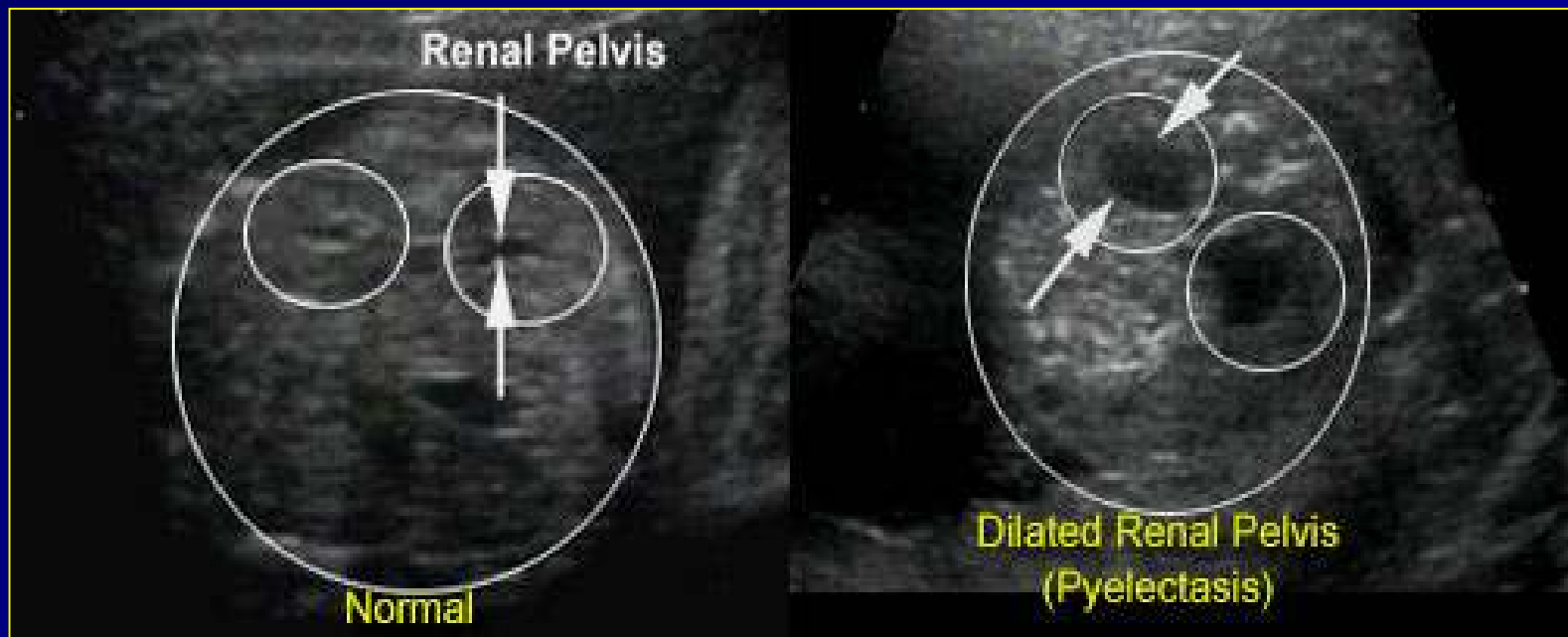


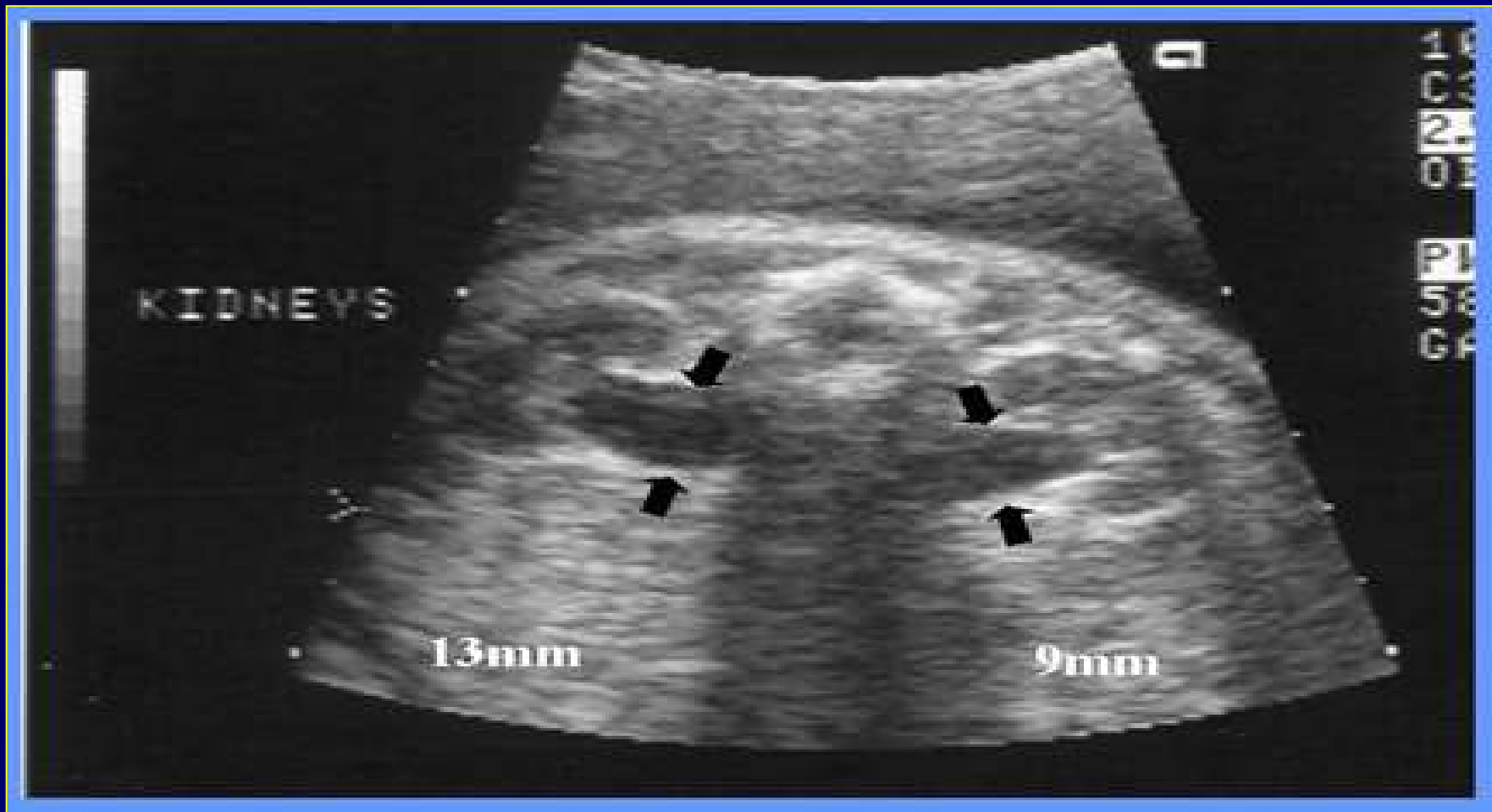
Humerus



MILD PYELECTASIS

- 0.3 to 4.5% of second trimester ultrasound
- Renal pelvis: $>5\text{mm}$ and $< 10\text{mm}$
- Hydronephrosis: $> 10\text{mm}$; structural abnormalities





- 25% Down's syndrome
- Progression of mild pyelectasis